

A close-up, grayscale photograph of a woman's face. An orange oval highlights a treatment area on her right cheek, and a light green oval highlights a treatment area on her left cheek.

Ellipse - I²PL

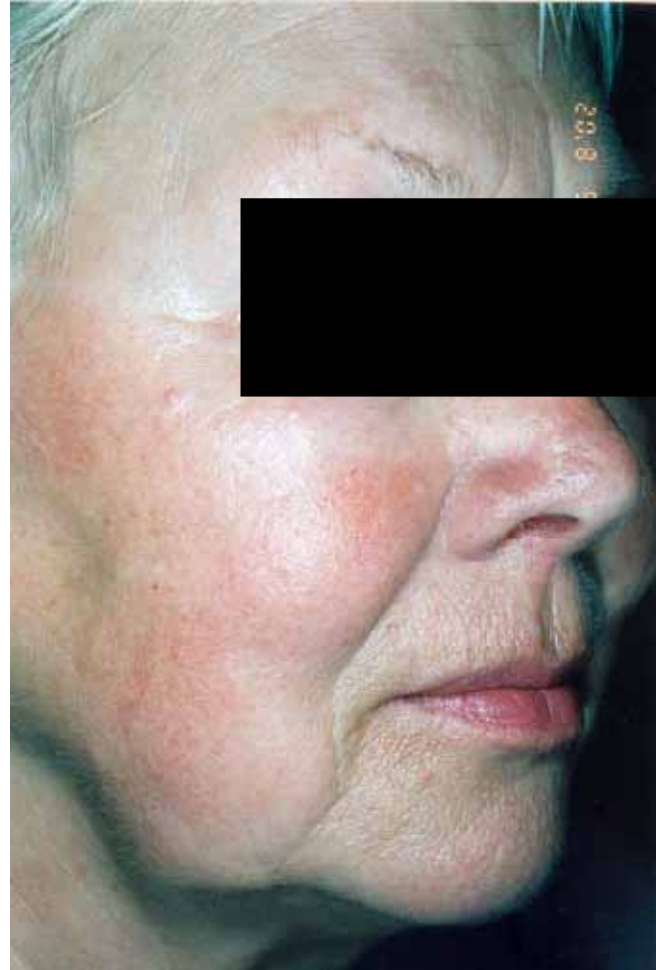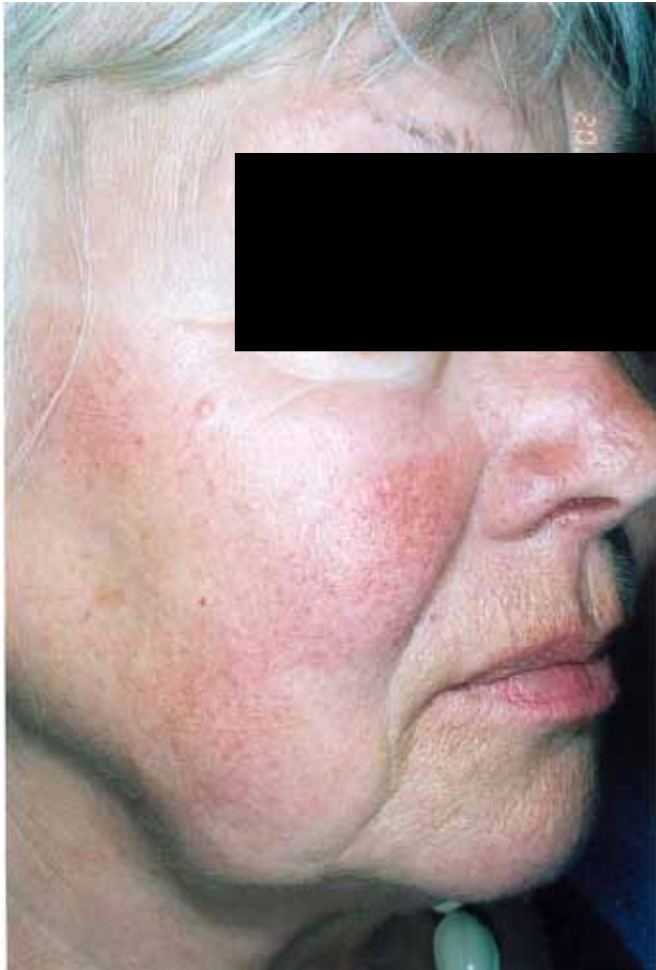**Before and After Pictures
Acne, Photo Rejuvenation,
Hair Removal, Vascular and
Pigmented Lesions**

BEFORE & AFTER ELLIPSE FLEX

CLINICALLY PROVEN

SAFE AND EFFECTIVE

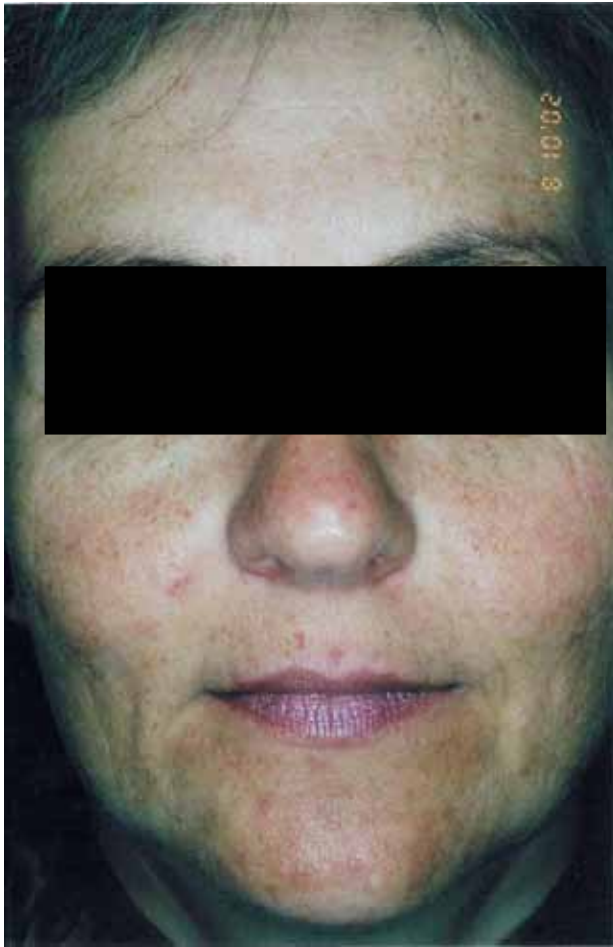
Photo Rejuvenation



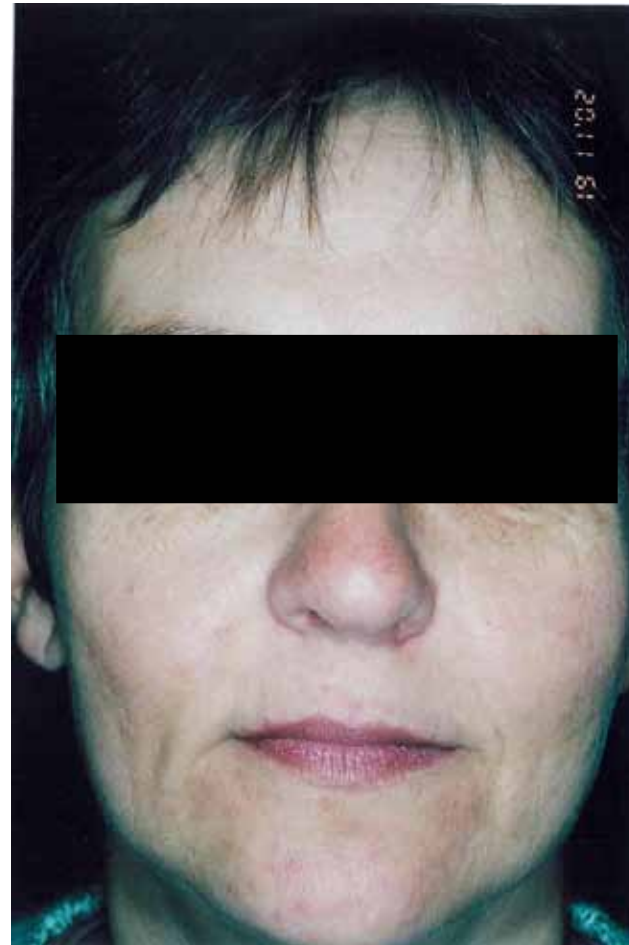Before and After 1 Treatment

Photo Rejuvenation

43 years old woman with epidermal melasma



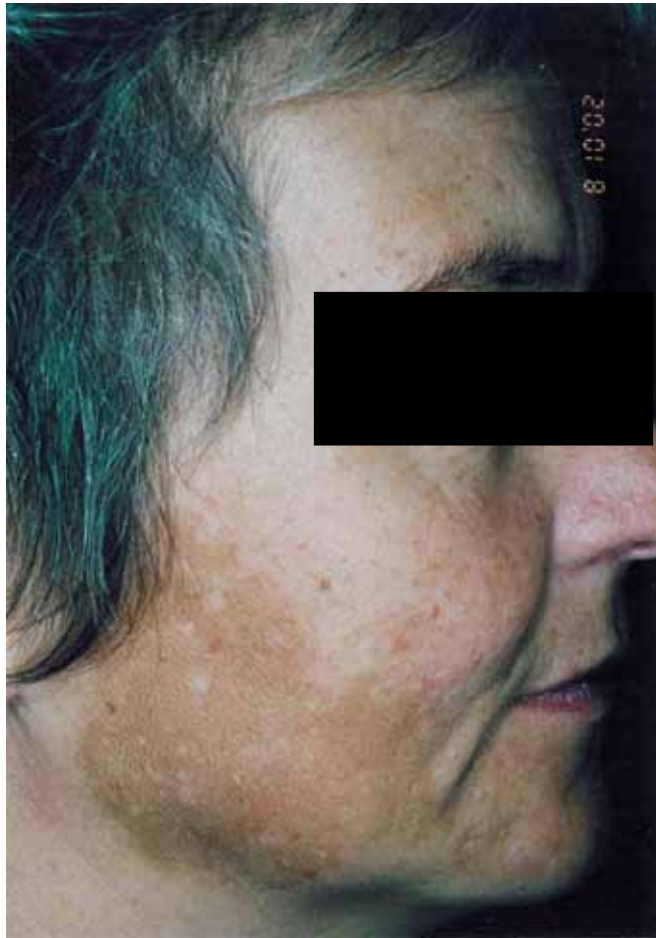Before



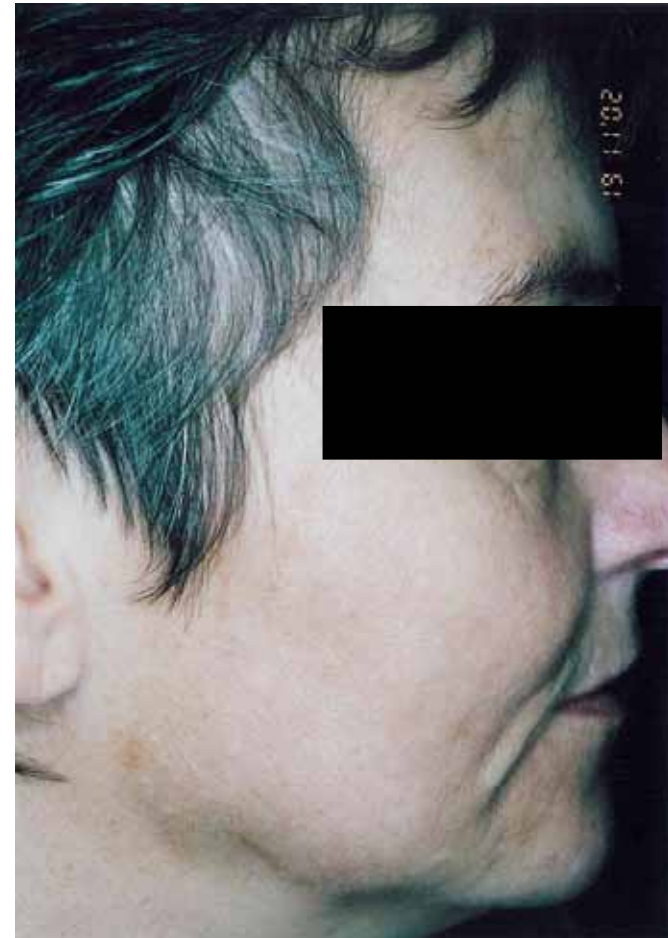One month after one treatment

Photo Rejuvenation

43 years old woman with epidermal melasma

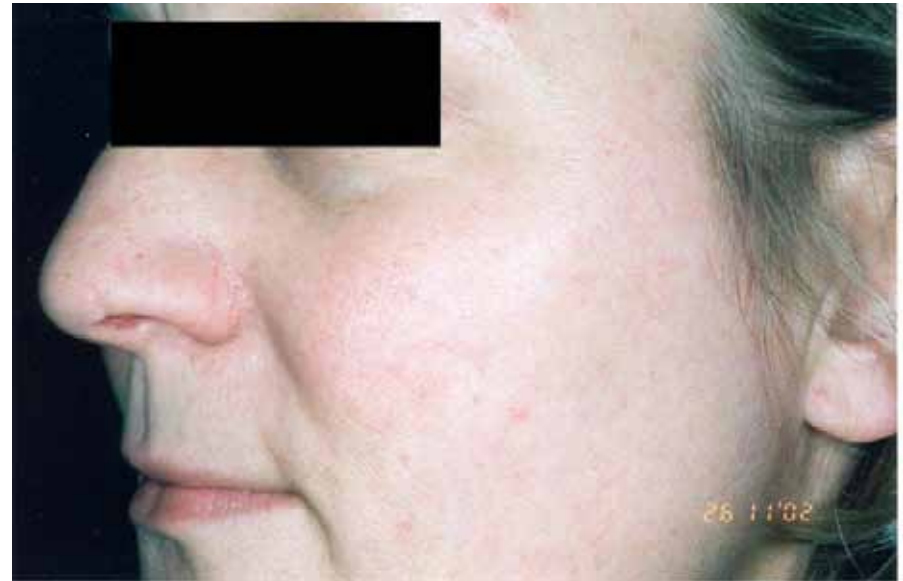
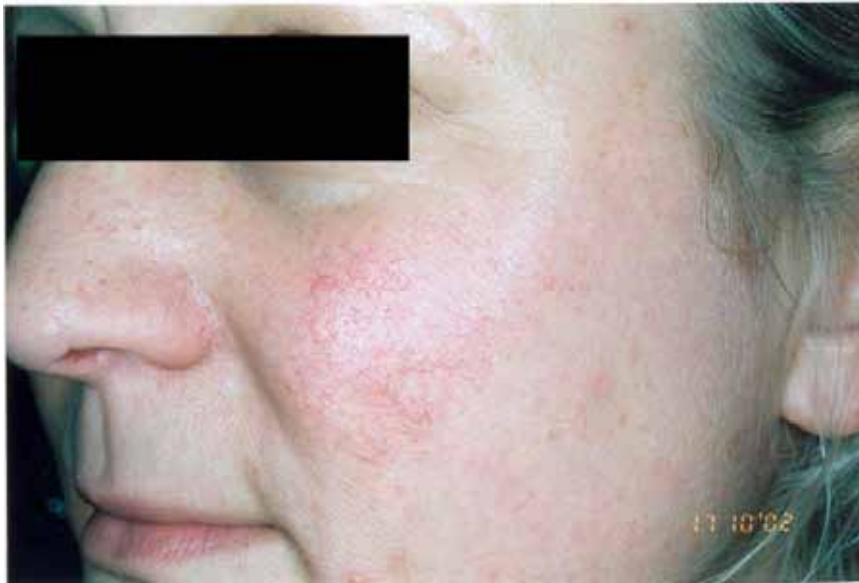
Before



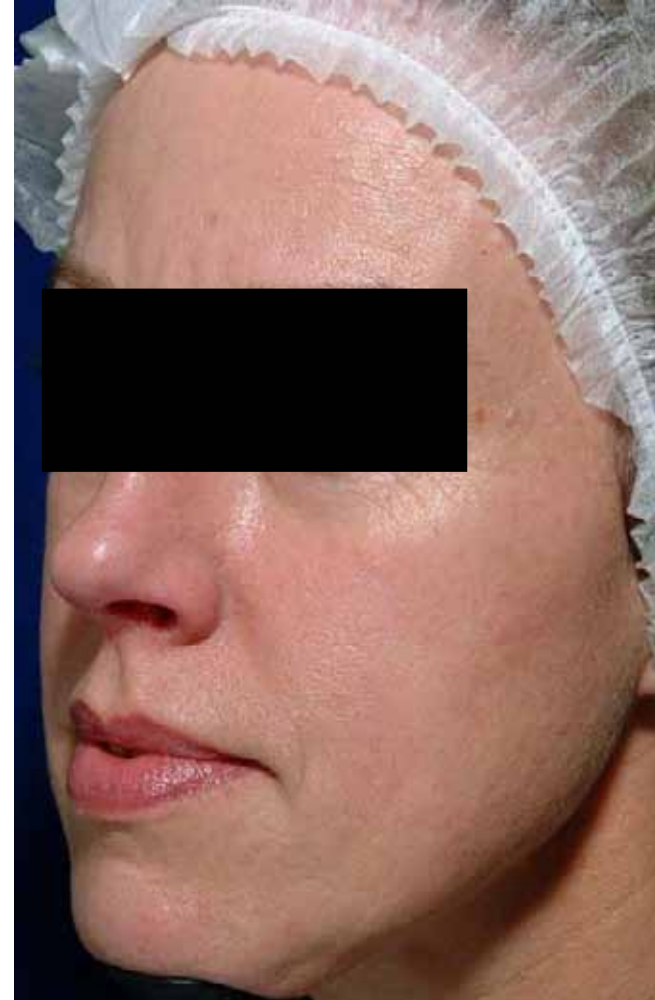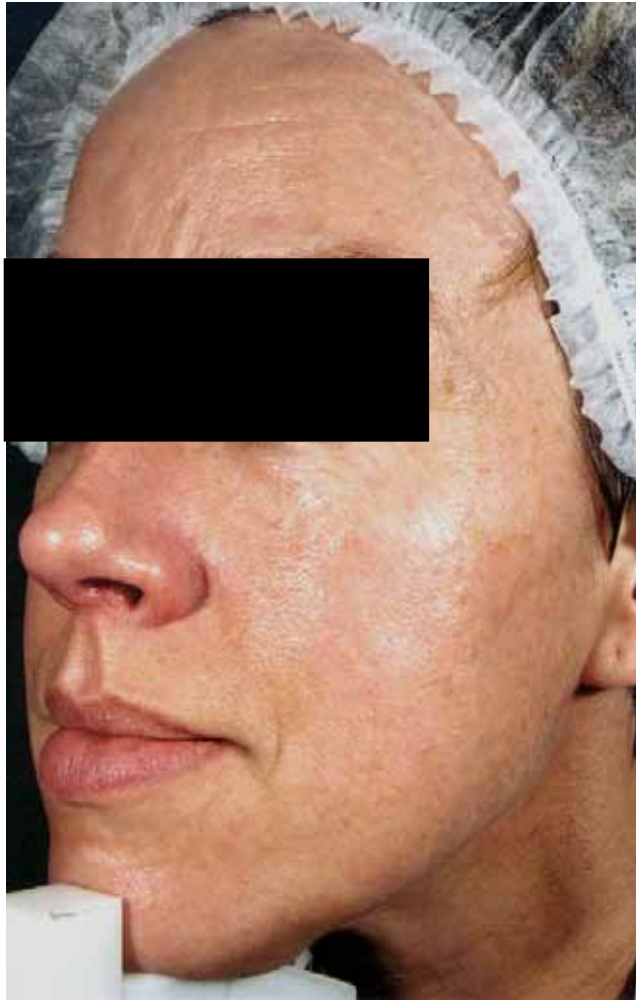One month after one treatment

Photo Rejuvenation



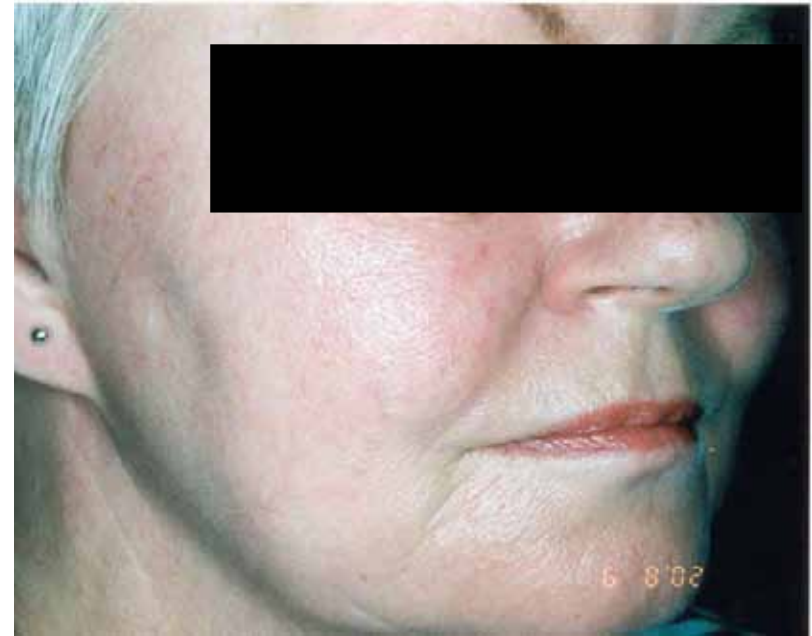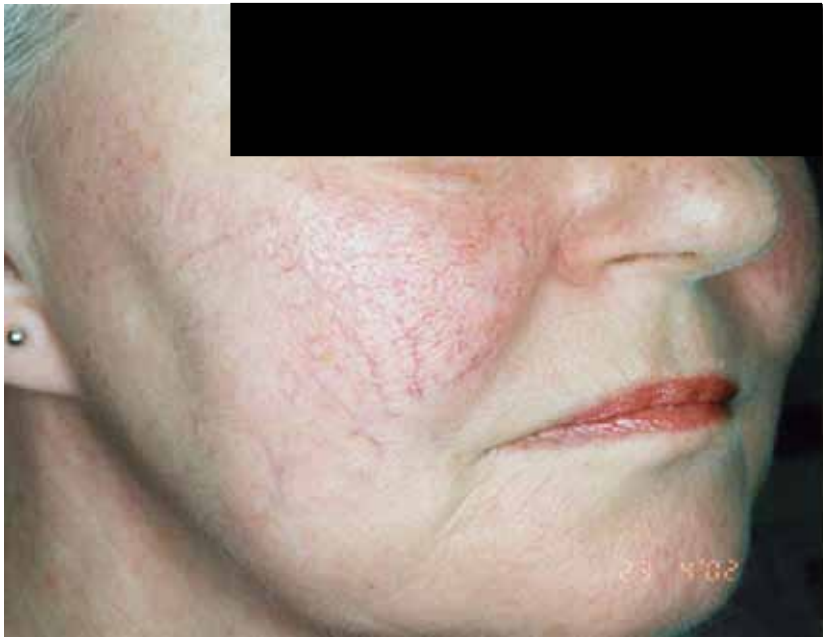Before and After 1 Treatment

Photo Rejuvenation



Before and After 1 Treatment

Photo Rejuvenation



Before and After 2 Treatments

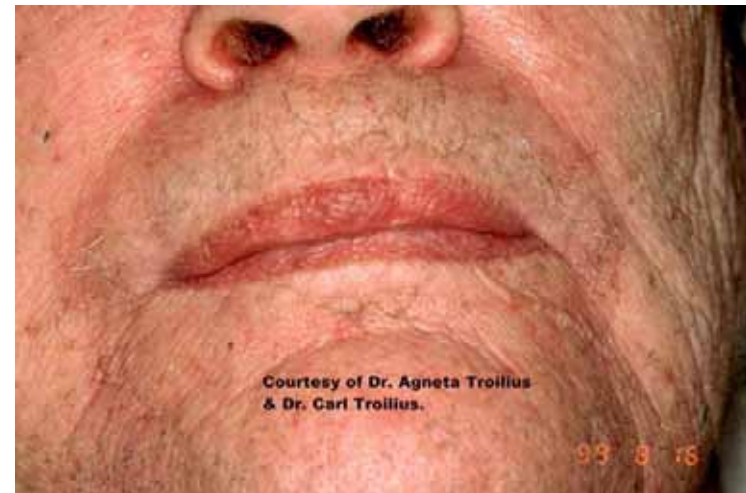
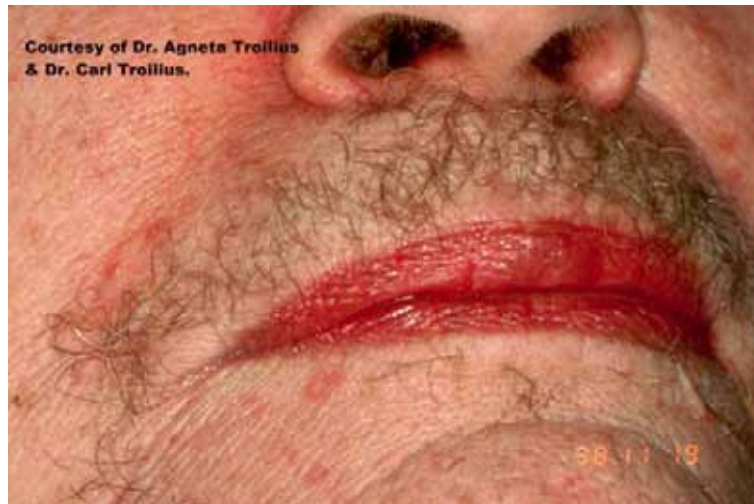Hair Removal

Female – 58 years old

After 4 treatments she was so satisfied that she declined

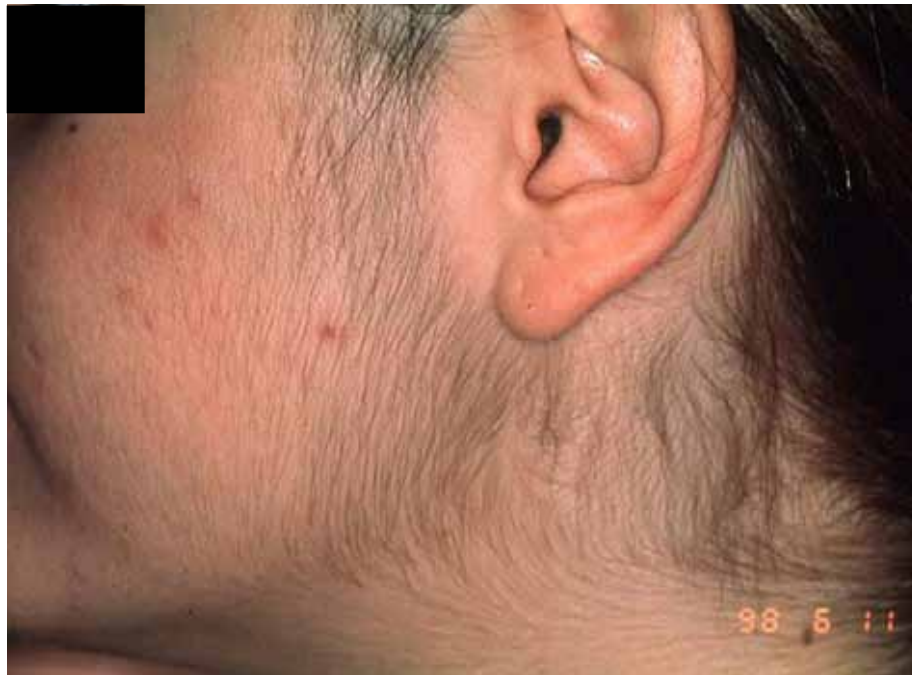from further treatments though they were offered to her free of charge.

The majority of the remaining hairs are white and cannot be treated.



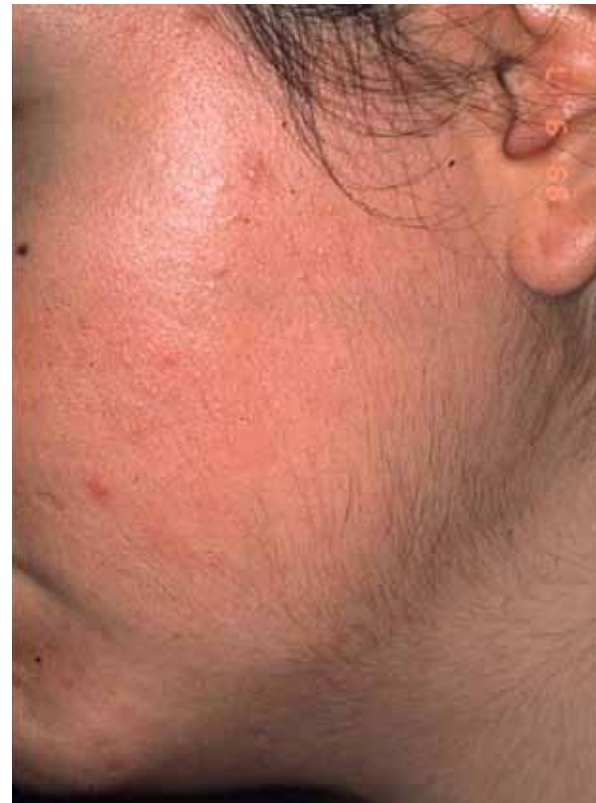Hair Removal

Whiskers



Courtesy of Dr. Agneta Troilius

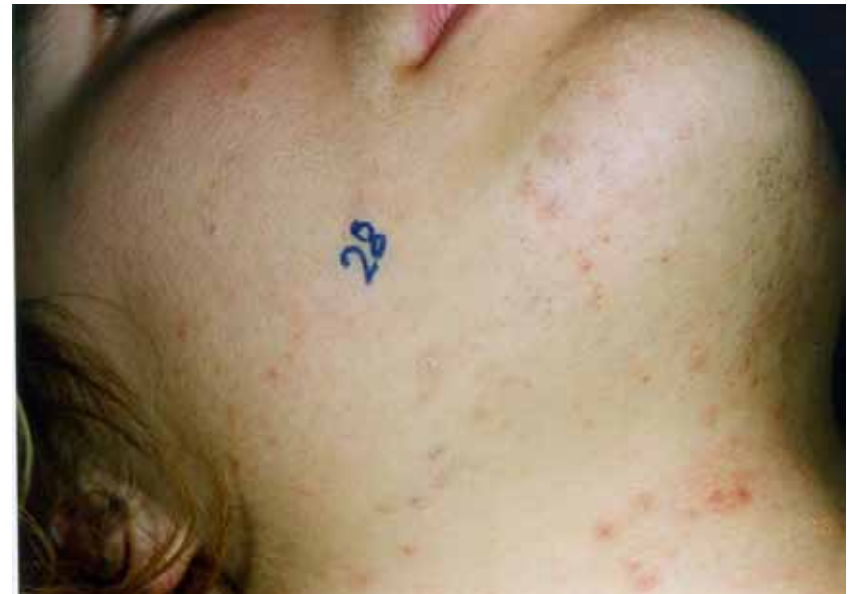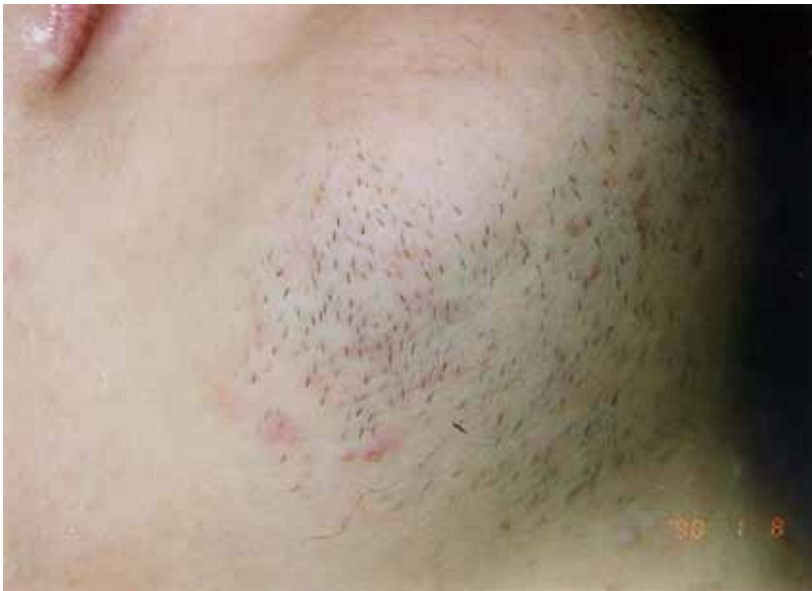Result after 2 treatments



Courtesy of Dr. Agneta Troilius

Hair Removal

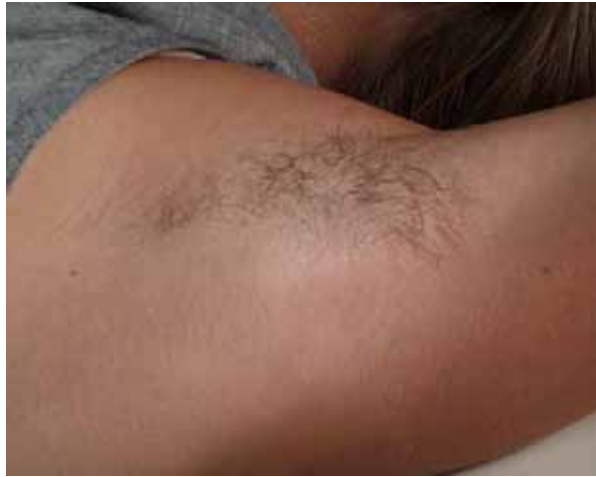Chin of a young female



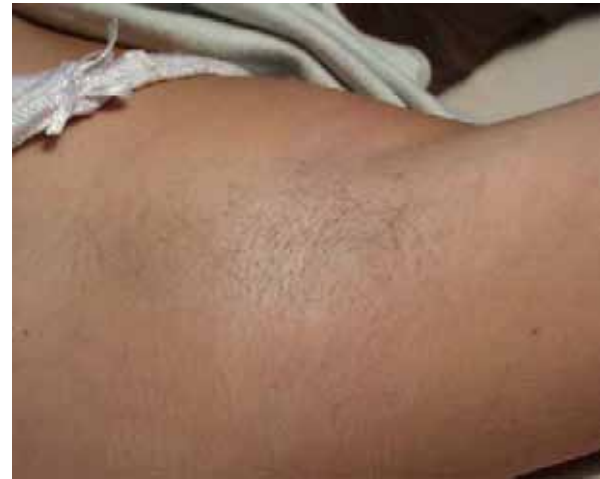Result after 3 treatments

Hair Removal

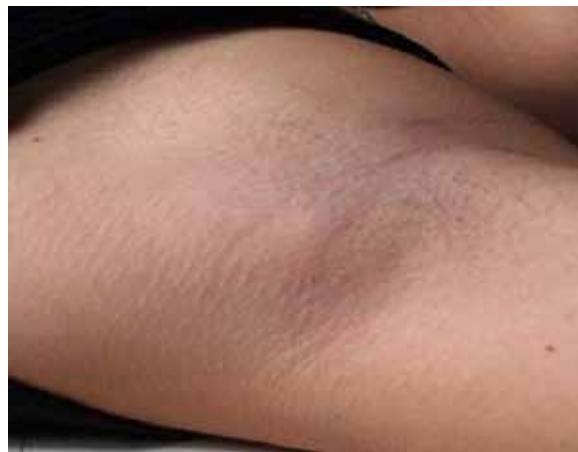Removal of hair in axillae of a young female



Before treatment



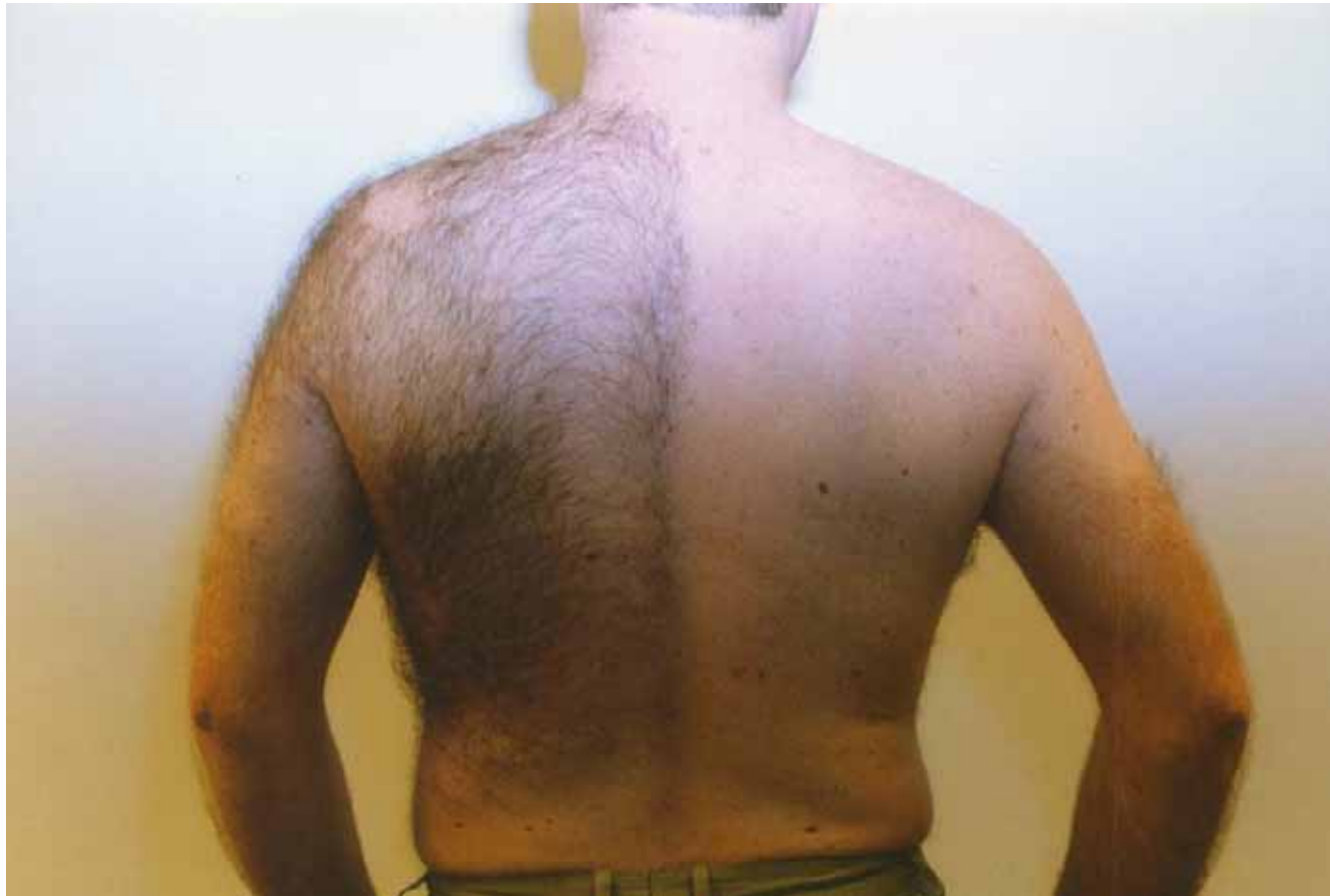Result after 2 treatments



Result after 3 treatments

Hair Removal

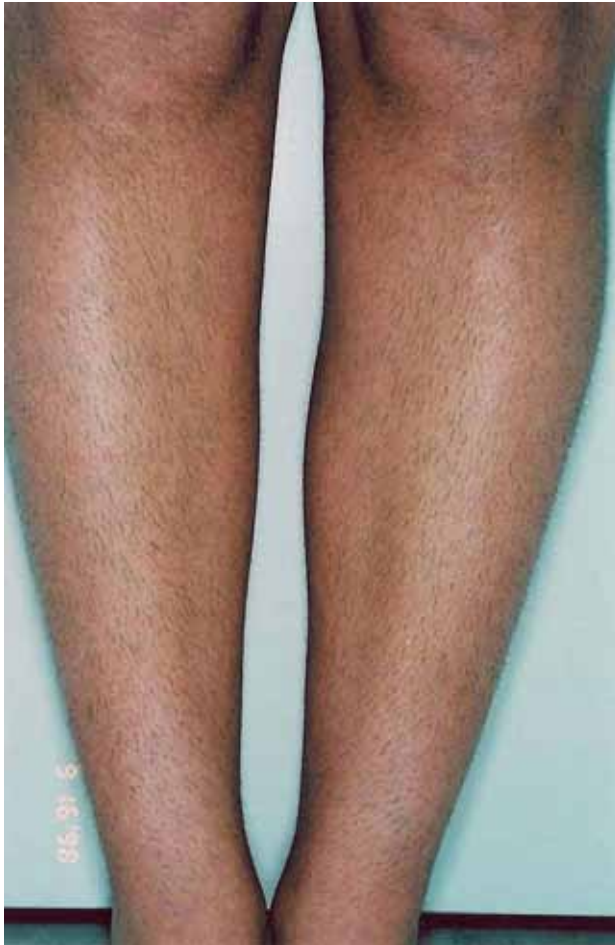Removal of hair on the back of a male



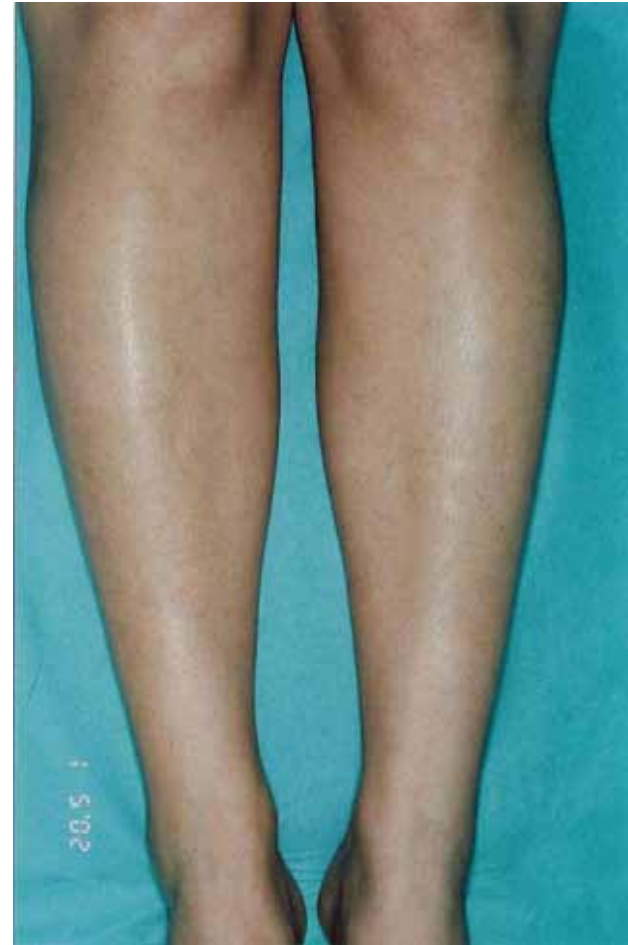Untreated area Result after 5 treatments

Hair Removal

Female patient suffering from Poly-cystic Ovary Syndrome



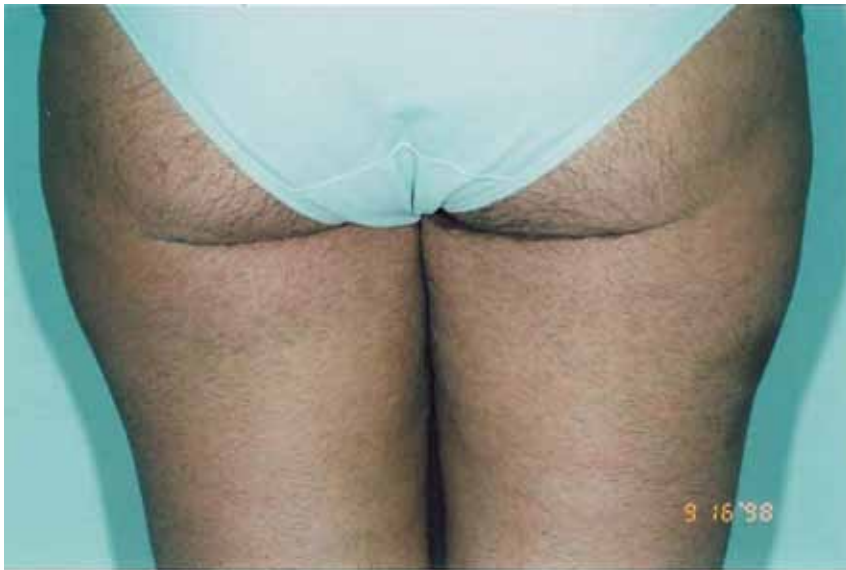Before treatment



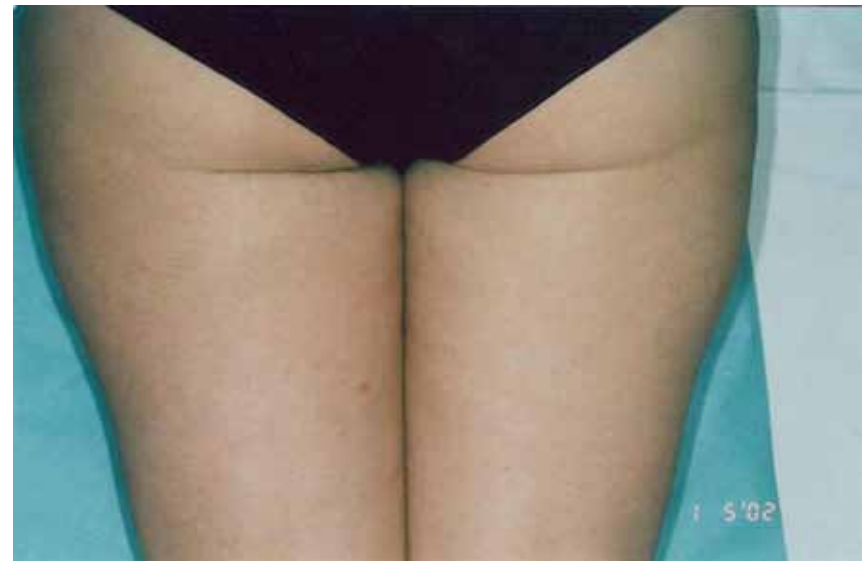After several treatments

Hair Removal

Female patient suffering from Poly-cystic Ovary Syndrome



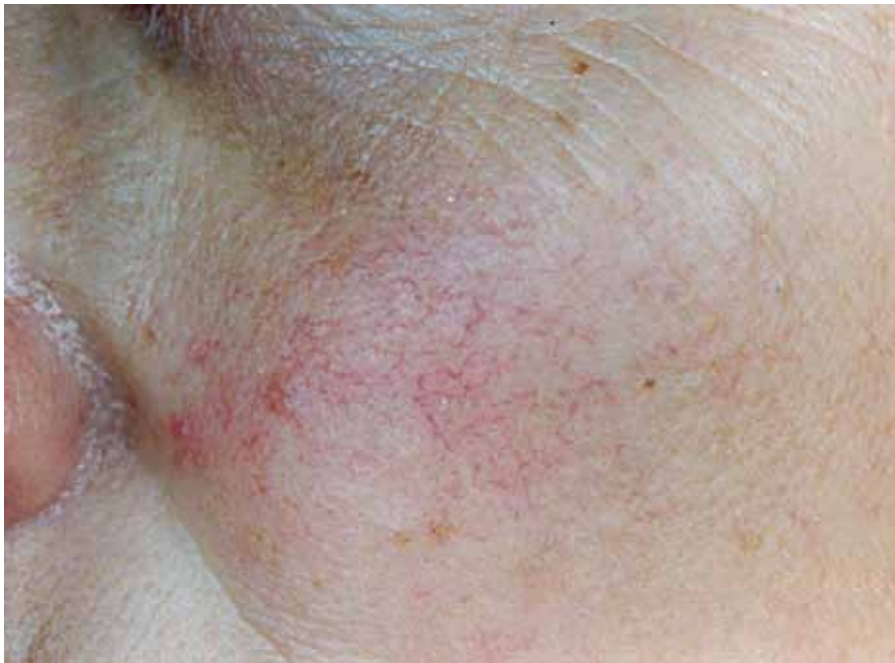Before treatment



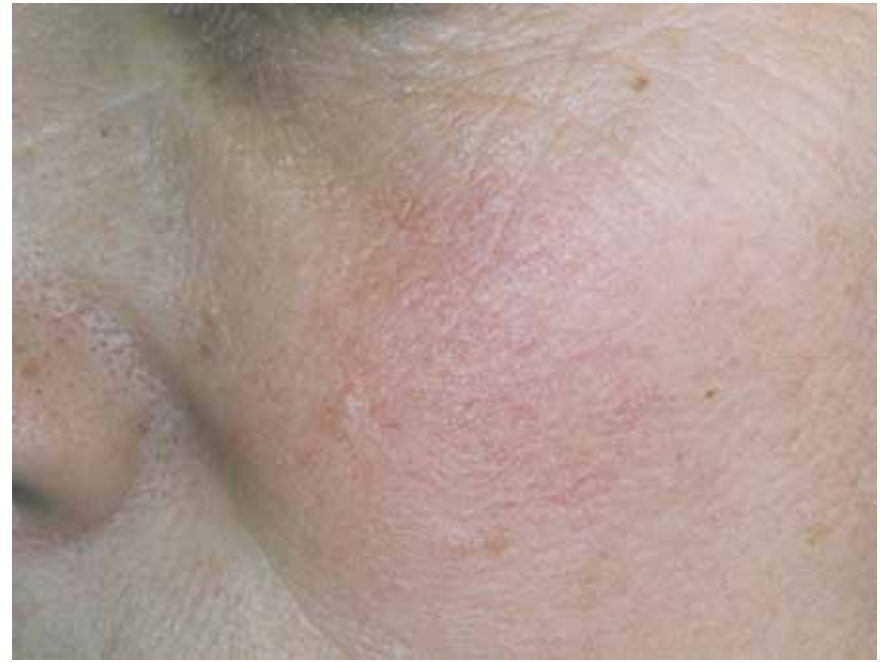After several treatments

Vascular Lesions

Vascular lesions of the cheeks



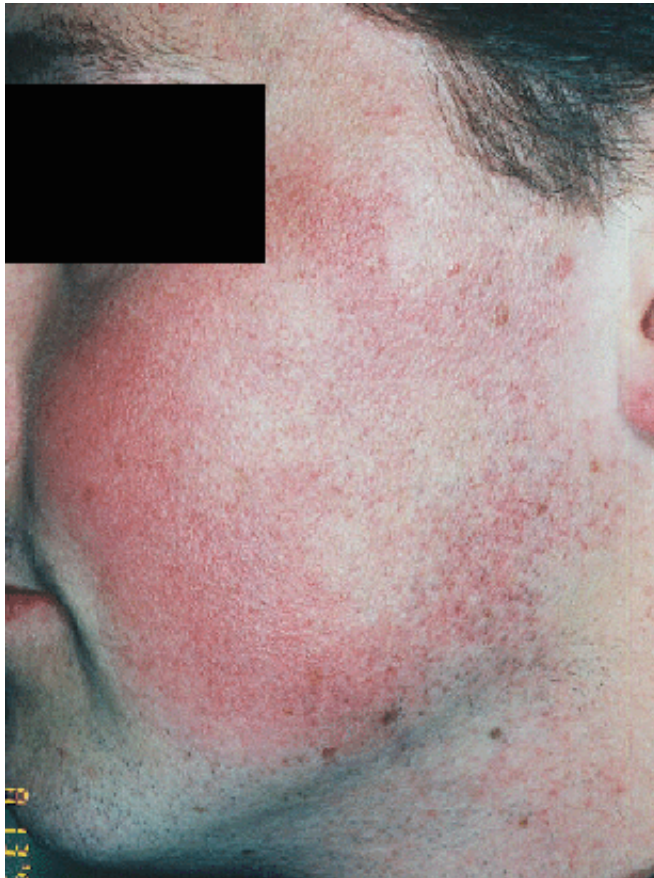Before treatment



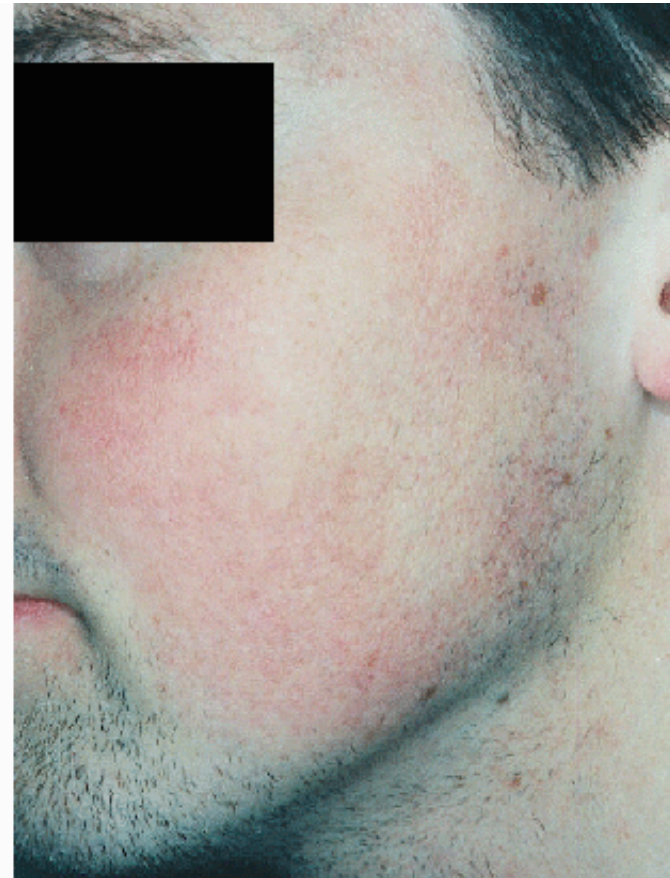After 2 treatments

Vascular Lesions

Diffuse redness



Before treatment



After 3 treatments